

**PATIENT**

Johnathon Ebersole

**SPECIES**

Feline

**BREED**

DSH

**SEX**

Male Neutered

**AGE**

4.2.08

**WEIGHT**

8.11lbs

**INTERPRETED BY**Maggie Machen Lamy,  
DVM, DACVIM  
(Cardiology)**HOSPITAL NAME**Fullerton Animal  
Hospital**REFERRING VET**

Dr. Unger

**INVOICE**

27763

**DATE**

12.1.22

**PRESENTING CLINICAL SIGNS**

History: Presented for annual exam and vaccines. History of hyperthyroidism. Routine monitoring bloodwork showed marked elevated BNP. History of grade 1/6 murmur not appreciated on most recent exam on 11/16. On exam HR of 240 bpm, waxy ears but otherwise unremarkable.

-Pertinent abnormal PE/Chem/CBC/UA Results: BNP 1321 (0-100)

-Current medications: Methimazole transdermal 5 mg BID, Gaba 100mg for echo today and last pm

-Sedation used: Torbugesic.

-Pertinent previous ultrasound results: No previous.

-STAT: Not requested.

-Imaging performed by: Stephanie Warga RDCS, RVT.

**ECHOCARDIOGRAM FINDINGS**

2D, m-mode, color flow and doppler imaging is available. The left ventricular wall is irregular with a focal septal thickening; however, the remainder appears normal. There is a mildly hyperechoic endocardium consistent with fibrosis. The papillary muscles are mildly hyperechoic. The left atrium is normal in size. The right atrium is normal in size. The right ventricle appears normal. The mitral valve is normal in structure and mobility with no MR. No TR. Blood flow through the RVOT is normal. The blood flow through the LVOT is normal on doppler; however, an intermittent LVOTO is suspected on color flow and 2D imaging. Mild to moderate AI. No pleural or pericardial effusion seen. No obvious cardiac tumors.

**CARDIAC CHART**

FELINE CARDIAC PARAMETERS	BODY WEIGHT (kg)	HR (BPM)	IVSd (cm) <small>(Moise, Pipers)</small>	LVIDd (cm) <small>(Moise, Pipers)</small>	LWVd (cm) <small>(Moise, Pipers)</small>	FS (%)	EF (%)
NORMAL PARAMETER	-----	150-240	3.5-0.55	<2 (mean 1.5)	3.5-0.55	35-67	80-100
PATIENT	3.7	NM	0.56	1.7	0.48	34	66
FELINE CARDIAC PARAMETERS	LA/AO <small>(Boon)</small>	LA/AO HEART BASE (Swe) <small>(Abbott)</small>	LA 2D short axis Base view (cm) <small>(Abbott)</small>		LVOT VEL (m/s)	RVOT VEL (m/s)	E max (m/s)
NORMAL	<1.5	<1.3	<1.2		<1.6	<1.3	<0.9
PATIENT	NM	1.3	1.4		1.7	1.7	NM

Adapted from June Boon, Veterinary Echocardiography, 1998  
 Abbott J & MacLean H JVIM 2006;20: 111-119, Moise et al. Am J Vet Res 47:1476, 1986. Pipers et al. Am J Vet Res 40:882, 1979.

## INTERPRETATION OF THE FINDINGS & FURTHER RECOMMENDATIONS

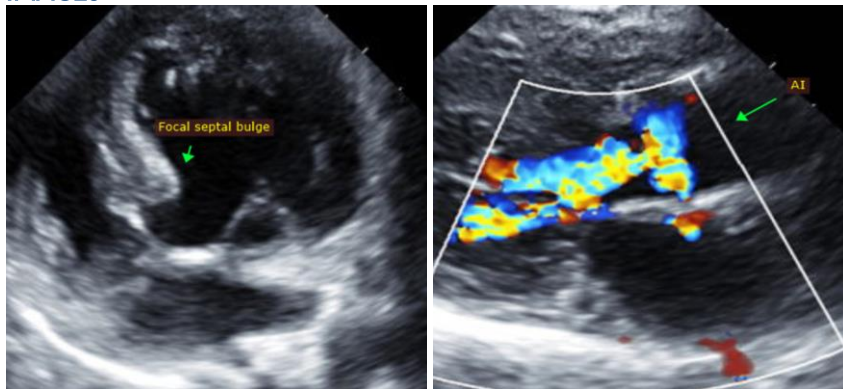
The primary abnormality identified is focal LV hypertrophy in addition to LV remodeling, which may be indicative of early hypertrophic disease or may simply represent a normal variant. The LA is normal which would indicate clinical stability. Serial echocardiography will be necessary to determine progression and clinical significance. Additionally, there is a mild LVOT obstruction. There is a mild LVOT obstruction that appears intermittent and does not warrant therapy. Finally, a significant aortic leak is noted, and a BP is strongly recommended. No additional issues are identified.

Anesthetic risk is considered mild, however judicious IV fluid rates are advised to avoid fluid overload. Additionally, drugs that stimulate heart rate should be avoided unless clinically necessary (glycopyrrolate, atropine). Avoid vasodilators as this may worsen the obstruction. A reasonable protocol includes opioid/benzodiazepine premedication, propofol induction, isoflurane maintenance. Additionally, steroids should be used with caution on older cats, as even a 'normal' geriatric heart can develop evidence of intolerance and fluid retention.

Monitor for any development of clinical signs, including labored breathing or signs of a blood clot (paralysis, neurologic change). Prognosis is guarded prior to assessing for progression.

A recheck echocardiogram is recommended in 6-12 months to screen for any evidence of progression.

## IMAGES



The information and recommendations provided are based on the images presented by the referring veterinarian. No evaluation can be communicated regarding pathology that was not visible in the image/video clips provided.

Thank you for this referral. This report was generated using transcription software, and minor dictation errors may be present. If the clinical or image interpretation does not parallel your findings or if I can be of any further assistance, please contact me.

**Maggie Machen Lamy, DVM**  
Diplomate of the American College of Veterinary Internal Medicine (Cardiology)  
info@sonopath.com